

## Correspondence

---

### Response to Claim of Error by Drug Enforcement Administration (DEA) Chemist in Calculating Quantity of Methadone Synthesized from Precursor Chemicals

Sir:

The March 1997 issue of the *Journal of Forensic Sciences* (J Forensic Sci 1997; 42(2): 349–50) includes correspondence from Morris Zedeck, Ph.D., regarding the calculation of the amount of methadone which could be synthesized from precursor chemicals at a clandestine laboratory site. We welcome the chance to respond to Dr. Zedeck because clarification may prove useful to laboratory personnel and the legal community.

In the case referred to by Dr. Zedeck, the theoretical yield in the reaction to synthesize methadone using diphenylacetonitrile as a precursor was calculated based on a 100% conversion of the precursor to final product. The reporting document used by DEA Chemists requires this calculation based on 100% conversion as a part of the standard protocol. The theoretical yield reported on this form does not allow for calculations based on stoichiometry, intermediates, or variations in synthetic pathways. To the extent a defendant can present evidence via expert testimony that a particular technique would yield less than 100%, he or she is free to introduce that testimony, and the court will make the ultimate decision whether to sentence based on the Government's 100% yield, the defendant's lesser yield, or on a figure someplace in the middle. See *United States v. Ramsdale*, 61 F.3d 825 (11th Cir. 1995); *United States v. Carroll*, 6 F.3d 735 (11th Cir. 1993), cert. denied, 510 U.S. 1183 (1994). But because we cannot predict the competency of the individual actually engaged in the manufacturing process, we must base our calculations on 100% conversion.

As to Dr. Zedeck's statement that "it is the weight of the methadone that determines the length of the sentence," we refer to 21 U.S.C. § 841(b) (1997), and to the United States Sentencing Commission *Guidelines Manual*, §2D1.1 ("Unless otherwise specified, the weight of a controlled substance set forth in the table refers to the entire weight of any mixture or substance containing a detectable amount of the controlled substance."), which direct that the weight of the controlled substance, and anything mixed with it, be included in the total weight used for sentencing purposes. Therefore, because separating the methadone from the structural isomer is very difficult and extremely rare in a clandestine laboratory setting, and because the mixture would have been in a useable form, it was proper to use the weight of the total substance and not just the weight of the controlled substance, methadone, for sentencing under Federal guidelines.

The reaction mechanisms described by Dr. Zedeck are well-known by DEA chemists. However, for the purposes of conforming to the legal statutes as they currently exist, the reporting mechanism

and the theoretical yield calculation were valid. The last paragraph of the correspondence leads the reader to believe that erroneous information was provided or would have been provided to the courts in the sentencing of the individuals involved in this case. This was not the case.

The two defendants in the case in question both plead guilty to "Conspiracy to Manufacture Methadone." One defendant received a sentence of two months in prison; the second defendant received a sentence of three years as a repeat offender.

Aaron P. Hatcher  
Associate Deputy Assistant Administrator  
Office of Science and Technology  
Drug Enforcement Administration

Cynthia R. Ryan  
Chief Counsel  
Drug Enforcement Administration

**Commentary on Yamazaki B, Hongcheng B, Tun Z, Ogura Y, Wakasugi C.** An electrocution death of an infant who had received an electric shock from an uncovered oval shaped lamp switch in his mouth while in the hospital. J Forensic Sci 1997 Jan; 42(1): 151–4

Dr. Yamazaki et al. reported of an unusual case of electrical induced death of an infant while in hospital. The death was nicely investigated and reported (1). However, I would like to disagree with their conclusion that the mechanism of death was ventricular fibrillation.

I agree with the authors that the pathway of the current was from one side of the infant's mouth to the other side, and that this circuit was created when he placed the switch into his mouth. The reasons for this are multiple and include the biphasic burn, shown to be on both the right and left side of the mouth, the lack of an alternative pathway to ground, as well as the absence of any other site of electrical burn. Numerous authors have suggested that electrocution deaths may occur without electrical burns or with but a single site of burn (2,3). However, with a prolonged circuit, as is apparent in this case, the absence of burns elsewhere on the body and the presence of two relatively discrete areas in the mouth, eliminates the possibility of a pathway other than from one side of the mouth to the other.

It would be helpful to know the nominal power rating of the light bulb contained within the lamp which was controlled by the switch. The fatal circuit had two resistive elements. First, there was the infant's moist mucous membranes which the authors suggest was 1000 ohms resistance. I would suggest that at 100 V, over such a small distance in an infant that the resistance would approach 200 ohms; which is the lowest measured resistance of humans (4). Presuming that the light bulb was rated at 100 watts, the resistance at 100 V would be 100 ohms. If the lamp were 50

watt the resistance of the lamp would be 200 ohms. The child's burns are compatible with some minutes of circuit at either the 300 ohms resistance with a 100 watt bulb or 400 ohms which would occur with a 50 watt bulb.

The observation that the switch was in the off position is further confirmation that the circuit was limited to the mouth and nearby structures. Had the switch been on, there would have been a parallel circuit one through the child the other through the switch. The child is 200 ohms, the switch probably less than 0.001 ohms. Thus had the lamp switch been switched on all of the current would have traveled through the switch. The nurse finding the body should have noted that the light was illuminated, but at a much reduced intensity due to the interposition of the resistance imposed by the mouth of the child. However, in the excitement of finding the child in extremis, such observations were probably not made, and the light would have gone out when the switch was pulled from the mouth. Had the light been burned out, or the bulb unscrewed, the child would have not been injured.

In disagreement with the authors, I feel that it is unlikely that the mechanism of death was ventricular fibrillation. First, the findings of extensive petechiae on the heart and lungs coupled with the presence of some increased lung weights strongly suggests the presence of an asphyxial death. The fact that the child had died face down with dorsal lividity evident, suggests that had the body been examined some hours after the initial autopsy that facial and palpebral petechiae may have become apparent. However, the absence of facial and palpebral petechiae does not rule out an asphyxial death, and the presence of heart and lung petechiae in a ventricular fibrillation death is extremely unusual.

Second, I conclude this was an asphyxial death because of the relative ease with which such a death is accomplished compared to the relative difficulty via ventricular fibrillation in this case. The circuit, even if the light bulb were as resistive a 50 watt bulb would result in a circuit of probably in the vicinity of 250 mamps. Professor Dalziel showed in men and women that in hand to hand circuits sufficient tetany of the muscles to preclude voluntary opening of the hand, the so called "let-go" value, at 16 mamps (5). This let-go value is felt to be somewhat lower for infants, although even Dalziel was unable to accomplish extensive studies on infants. The current flow in the mouth and lips will create a field electron flow phenomena with the greatest flow directly between the two sides of the open switch, but with some flow radiating outward along radial pathways of greater distance. These longer pathways will be associated with diminished current density compared to the most direct route between the two points. As long as the current flow approaches 16 mamps, the muscles will be in tetany. With the points across the lips, it is quite likely that this tetany included the muscles as far away as the pharyngeal constrictors, as well as the tongue and perhaps the laryngeal muscles. The contraction of these would account for an upper airway obstruction. This would have been more pronounced had there been nasal obstruction, either from the febrile illness which brought the infant to the hospital, or some degree of congenital nasal obstruction which was not noted in the report.

Therefore, ventricular fibrillation seems unlikely because the heart is considerably further away from the circuit than the musculature of the tongue and neck and because the current flow to fibrillate the infant heart is significantly more than the 100 mamps required as the threshold to fibrillate adult hearts (6), while tetany probably occurs at a current flow less than the 16 mamps required for adults.

## References

1. Yamazaki M, Hongcheng B, Tun B, Ogura Y, Wakasugi C. An electrocution death of an infant who had received an electric shock from an uncovered oval shaped lamp switch in his mouth while in the hospital. *J Forensic Sci* 1997;42:151-41.
2. Tatum E. Death from electric currents. *NY Med J* 1890;51:207-209.
3. Wright RK. Death or injury caused by electrocution. *Clin Lab Med* 1983;3:343-53.
4. Spitka AJ, Radasch HE. The brain lesions produced by electricity as observed after legal electrocution. *Am J Med Sci* 1912;144:341-347.
5. Dalziel CF, Lee WR. Let-go currents and voltages. *AIEE Trans* 1956;75:49-56.
6. Dalziel CF, Lee WR. Lethal electrical currents. *IEEE Spectrum* 1967;4:44-50.

Ronald K. Wright, M.D., J.D.  
Department of Pathology  
Division of Forensic Pathology  
Jackson Memorial Hospital  
P.O. Box 016960  
Miami, FL 33101

## Author's Response

Sir:

Thank you for the valuable commentary upon our report. It is beneficial to point out another mechanism of death in the reported case.

Dr. Wright concluded that the direct cause of death was an asphyxial death because upper airway was obstructed by tetany of pharyngeal and laryngeal muscles due to electrocution. We agree that partial or complete upper airway obstruction could occur in the cases of electrocution. We approve of his indication. However, can we explain the direct cause of death was only and truly an asphyxial one? May we assume that ventricular fibrillation was unlikely to occur?

We still would like to disagree that the direct cause of death was an asphyxial one, after agreement of upper airway obstruction could have occurred. We explain the reasons as follows.

First, the findings of extensive petechiae on the lungs and pericardial membrane are general findings recognized in the cases of acute death, and are not specific for autopsy findings of asphyxia (1). And petechiae in the epicardium are often recognized in electrocution death cases, although they are not specific finding of electrocution (2,3). He assumed that mild lung edema was caused by asphyxia, but mild lung edema is a general finding recognized in the cases of acute death, and is not specific for autopsy findings of asphyxia. Pulmonary edema and petechial hemorrhages are usually encounter in cases of electrocution (3).

Second, blood volume of the organs such as liver, spleen, kidney were normal, and not congested.

Third, the infant was found dead in prone position but turned up immediately. Eight hours postmortem had already passed at the time of the autopsy, and postmortem lividity occurred on his back. The face was pale. The palpebral conjunctivae were also pale, and petechiae under the palpebral conjunctivae were not recognized (Fig. 1). Petechiae, were not recognized on the face either. If petechiae existed in the palpebral conjunctivae, they should have been recognized at the time of autopsy, as extensive petechiae had been recognized below lungs' surface. If the direct cause of death was emphasized as asphyxial one, the reasons why no petechiae were recognized on the face not in the palpebral conjunctivae, and why internal organs were not congested should be fully explained, although under the condition of which can

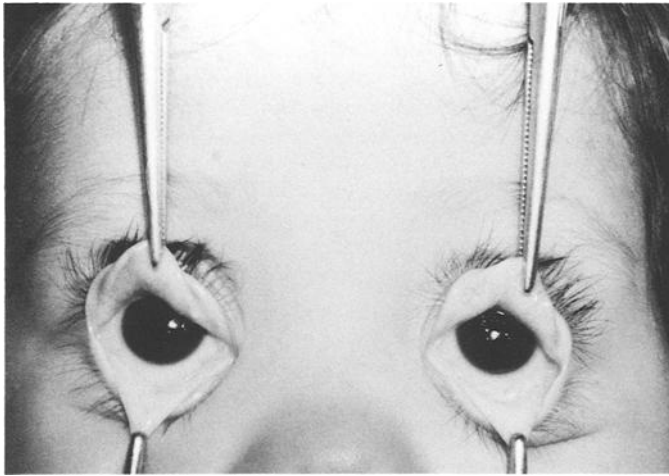


FIG. 1—Absence of petechiae.

produce typical asphyxial death. We think the autopsy diagnosis of 'asphyxia' should be done circumspectly so long as electric marks are recognized. In fatal electrocution, the usual mode of death is cardiac arrhythmia leading to ventricular fibrillation and arrest. In these cases, there is little to discover at autopsy apart from the skin lesions and the corpse is either pale or only slightly congested in general (2). On the basis of the autopsy findings in the present case, it is not contradictory to assume that the direct cause of death was ventricular fibrillation.

Fourth, the electric bulb containing within the lamp at the scene was shown to be 60 W. If we suppose that the resistance of the mucosa of the mouth and lips is  $200 \Omega$  as he asserts, the resistances of the electric bulb and the body are arranged in series, and the total resistance rates about  $370 \Omega$ . Under this condition, the current flow in the mouth and lips is approximately 270 mA. This current itself is quite enough to produce ventricular fibrillation in the infant. He insists that an electric current radiate outward along radial pathways of greater distance and these longer pathways will be associated with diminished current density compared to the most direct route between the two points. But he didn't mention at all which degree and how the current decreases in details. Tissue between the mouth and the heart is not an insulator. Would it be a natural way of thinking that ventricular fibrillation have occurred? Buccal mucosa is continuous with that of esophagus and trachea. Because the resistance of mucosa is originally low as he asserts, it is not contradictory to assume that fatal current arrived to the heart.

On the basis of these reasons, we explain the direct cause of death of the present case as follows. We presume that upper airway obstruction would be produced when the pendant switch with live current was put into the mouth and ventricular fibrillation would also be produced at the same time. Electric current is so fast that when electrocution occurs, the current may reach pharyngeal and laryngeal muscles and heart simultaneously. In general, asphyxia is manifested in a well-defined sequence of symptoms—dyspnea, convulsions, apnea and the final stage. The heart may continue to beat for a period after respiration has ceased. The time course of asphyxia is approximately estimated by 4–10 min to the complete cardiac arrest (4). On the other hand, when ventricular fibrillation occurred, it is estimated that even cardiac arrest does not occur in a second but in some dozens of seconds or in 1 min. In other words, cardiac arrest occurs in the final stage of the time course of asphyxia, but ventricular fibrillation directly cause cardiac arrest.

During that very short period, ventricular fibrillation set in before complete time course of upper airway obstruction could have occurred. Therefore, typical signs of asphyxia did not appear when the infant was dead.

In summary, ventricular fibrillation will cause the cardiac arrest in more shorter time when compare with asphyxial death by upper airway obstruction. It is established that respiratory movements may continue for up to 1 or 2 min after the onset of ventricular fibrillation in experimental observation (5). Even in those cases, total time cause of the death is shorter than that of asphyxial one.

Therefore, asphyxia by upper airway obstruction exerts a bad influence upon the direct cause of death, but asphyxia itself would not be the direct cause of death in the present case. Electric marks might have been formed after death until the infant was found. We assume that the electric marks must have formed utmost within 1 or 2 min from the time of electrocution under consideration of postmortem electric mark formation.

### References

1. Knight B. Forensic pathology. 2nd ed. London: Arnold, 1996;345–351.
2. Knight B. Forensic pathology. 2nd ed. London: Arnold, 1996;319–330.
3. Somogyi E, Tedeschi CG. Injury by electrical force. In: Tedeschi CG, Eckert WG, Tedeschi LG, editors. Forensic medicine: a study in trauma and environmental hazards. Philadelphia: Saunders, 1977;645–676.
4. Ponsold A. Lehrbuch der Gerichtlichen Medizin. Thieme: Stuttgart, 1967;314–319.
5. Lee WR. The mechanism of death from electric shock. Med Sci Law 1965;5:23–28.

Motohiko Yamazaki, M.D.  
Department of Legal Medicine  
Osaka University Medical School  
2-2 Yamada-oka  
Suita, Osaka 565  
Japan

**Commentary on Moriya F, Hashimoto Y.** Postmortem diffusion of tracheal lidocaine into heart blood following intubation for cardiopulmonary resuscitation. *J Forensic Sci* 1997 Mar; 42(2):296–99. Postmortem drug diffusion from the airways

Sir:

I read with considerable interest the report by Moriya and Hashimoto (1) on the postmortem diffusion of tracheal lidocaine into the blood after intubation in three individuals whose heart beat was not restored by cardiopulmonary resuscitation. As far as I am aware these are the first case reports documenting postmortem diffusion of a drug, other than ethanol, following airways contamination. In their cases the lidocaine was deliberately introduced into the trachea during resuscitation. However, the potential for postmortem diffusion of drugs from the airways also exists following agonal or postmortem contamination. In a significant minority of autopsies there is contamination of the airways by "vomitus" which may be the result of agonal aspiration or alternatively post-mortem artefact. After death relaxation of the oesophago-gastric sphincter allows passive reflex of gastric contents into the oesophagus and mouth with the potential for airways contamination, which may be facilitated by body handling. Should the contaminating "vomitus" contain alcohol or drugs then these will readily diffuse from the airways into cardiac blood, as demonstrated by a human cadaver model (2,3). It seems that, for a given quantity of drug,

postmortem diffusion from airways contamination into cardiac blood is more extreme than diffusion from gastric residue. This is not surprising given the effectiveness of inhalation as a method of drug administration in the living.

Moriya and Hashimoto noted a much higher concentration of the diffusing lidocaine in left ventricular cardiac blood when contrasted with right ventricular blood, and also a lower concentration in pericardial fluid. They speculate that this is the result of the relative anatomical positions of the ventricles in a supine cadaver. This diffusional pattern can be reproduced in a cadaver model (3) and an alternative possible explanation is easier diffusion of the toxicant from the airways through the thin walled pulmonary veins and thence into the pulmonary venous blood and left heart blood, when contrasted with diffusion through the thicker walled pulmonary arteries and thence into pulmonary arterial blood and the right heart. Finding a lower concentration of the toxicant in pericardial fluid when contrasted with cardiac blood appears to be characteristic of postmortem diffusion from the trachea, with the implication that the toxicant may enter the pericardial fluid by diffusion via the pulmonary vessels rather than directly. By contrast post mortem diffusion of drugs from gastric residue produces a higher concentration in pericardial fluid than in cardiac blood suggesting that the diffusional pathway may be via the pericardial fluid and thence into the cardiac blood, which is in accord with the anatomical relationships. Whatever the pathway of diffusion, what is clearly impressive is the power of diffusion as a physical phenomenon in a cadaver.

From a practical perspective the report of Moriya and Hashimoto (1) re-emphasises the importance of sampling femoral venous blood for autopsy toxicology, and avoiding torso blood samples.

## References

1. Moriya F, Hashimoto Y. Postmortem diffusion of tracheal lidocaine into heart blood following intubation for cardiopulmonary resuscitation. *J Forensic Sci* 1997;42(2):296-299.
2. Pounder DJ, Yonemitsu K. Postmortem absorption of drugs and ethanol from aspirated vomitus: an experimental model. *Forensic Sci Int* 1991;51:189-195.
3. Fuke C, Berry CL, Pounder DJ. Postmortem diffusion of ingested and aspirated paint thinner. *Forensic Sci Int* 1996;78:199-207.

Derrick J Pounder  
Department of Forensic Medicine  
The Royal Infirmary  
Dundee, Scotland

## Authors' Response

Sir:

We greatly appreciate Professor Pounder's special interest in our article (1). Xylocaine™ jelly, a 2% lidocaine hydrochloride preparation, is often in Japan used to facilitate endotracheal intubation for cardiopulmonary resuscitation. Of all forensic autopsy

cases seen at our department, 20-30% were patients who had undergone cardiopulmonary resuscitation with endotracheal intubation. About 42% of these patients were positive for intubation-related lidocaine. Therefore, in such patients, special attention should be paid to postmortem diffusion of tracheal lidocaine, and lidocaine concentrations in heart blood should not be used for evaluation of lidocaine toxicity. The possible pathways of postmortem diffusion of tracheal lidocaine into heart blood are: 1) direct diffusion across a concentration gradient, and 2) diffusion via pulmonary vessels. Irrespective of which pathway is dominant, the blood in the left cardiac chambers may be affected more markedly than that in the right cardiac chambers in a supine position during the early postmortem period, since the former are anatomically located below the latter in this position. However, as Professor Pounder states, the much lower concentrations of lidocaine in the pericardial fluid than in the blood in the left cardiac ventricles in our cases strongly suggest that tracheal lidocaine diffuses mainly via pulmonary vessels during the early postmortem period. Lidocaine may diffuse into thin-walled pulmonary veins faster than into thicker-walled pulmonary arteries, and thence into the left cardiac chambers. This proposed mechanism can also be supported by findings such as the much higher concentrations of lidocaine in the lungs than in thoracic fluids. The lidocaine concentrations in the pericardial fluids might become higher than those in the blood in the left cardiac chambers, provided a large proportion of tracheal lidocaine diffuses directly into the heart blood. Since the lungs have the richest supply of blood vessels in the body, tracheal lidocaine can easily diffuse into pulmonary vessels. Thus, the pathway of postmortem diffusion of tracheal lidocaine into heart blood appears to be very similar to that of some basic drugs deposited in the lungs at much higher concentrations than in blood. In our experience, postmortem redistribution of pulmonary drugs into heart blood seems to be suppressed strongly by clotted blood in the pulmonary vessels and cardiac chambers, even if the pulmonary drug concentrations are much higher than in blood (2). Should blood remain in liquid form after death, then pulmonary drugs may quickly diffuse into the blood in the right cardiac chambers via the pulmonary veins (3). This explanation needs to be substantiated by an in-depth investigation.

## References

1. Moriya F, Hashimoto Y. Postmortem diffusion of tracheal lidocaine into heart blood following intubation for cardiopulmonary resuscitation. *J Forensic Sci* 1997 Mar;42(2):296-99.
2. Moriya F, Hashimoto Y. Tissue distribution of five psychoactive drugs detected in a multiple drug-related death of a man in the elimination phase of those drugs. *Res Pract Forens Med* 1996 Dec;39:185-92 (abstract in English).
3. Moriya F, Hashimoto Y. Distribution of free and conjugated morphine in body fluids and tissues in a fatal heroin overdose: is conjugated morphine stable in postmortem specimens? *J Forensic Sci* 1997 Jul;42(4):734-8.

Fumio Moriya, Ph.D.  
Associate Professor  
Yoshiaki Hashimoto, M.D.  
Professor  
Department of Legal Medicine  
Kochi Medical School  
Kohasu, Oko-cho, Nankoku City, Kochi 783  
Japan